

## Implications of COVID-19–associated Coagulopathy on Reconstructive Surgery: A Case of Ongoing Tissue Necrosis

David Dugue, BS; Kun-Tai Hsu, MD; I. Janelle Wagner, MD; Christine M. Jones, MD

The coronavirus disease 2019 (COVID-19) pandemic has created a massive health crisis, with over 54 million cases and 1.3 million deaths globally as of November 2020.<sup>1</sup> Several studies have implicated COVID-19 associated coagulopathy (CAC) as an important contributor to morbidity and mortality in select patients.<sup>2–4</sup> Although the pathogenesis is poorly understood, CAC is known to be an acute, acquired hypercoagulable state with coagulation profile changes, including elevated D-dimer and fibrinogen, prolonged prothrombin time, and blood hyperviscosity.<sup>2,3</sup> CAC is associated with digital gangrene, acute limb ischemia, and venous and arterial thrombosis.<sup>2,3</sup> A potential sequela of this hypercoagulability is ongoing tissue necrosis of reconstructed wounds—a phenomenon that has not been previously described.

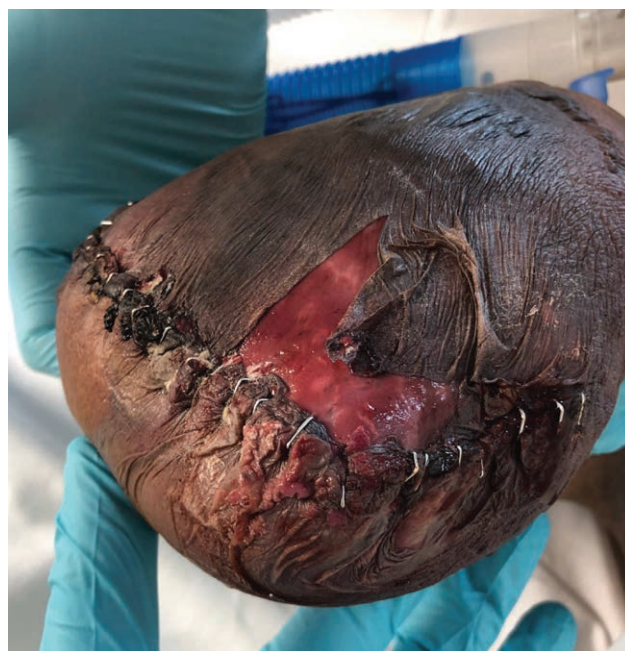Our experience is illustrated by a 68-year-old man with a history of hypertension and end-stage renal disease who presented in hypoxemic respiratory failure and shock. Nasopharyngeal swab was positive for SARS-CoV-2. He was started on high-dose corticosteroids, empiric antibiotics, and titrated vasopressors. Admission labs included white blood cell count: 17.6K/mm<sup>3</sup> (normal: 4.0–11.0K/mm<sup>3</sup>), lymphocyte count: 0.3K/mm<sup>3</sup> (1.0–4.8K/mm<sup>3</sup>), D-dimer: >128,000 ng/mL (0–500 ng/mL), fibrinogen: 156 mg/dL (200–385 mg/dL), and prothrombin time: 15.6 seconds (10.6–13.7 seconds). Within 24 hours, the patient developed a cold, mottled right arm up to the elbow, without demonstrable flow through radial or ulnar arteries. Emergent right brachial, radial, and ulnar embolectomy was performed, with fasciotomies demonstrating necrotic forearm musculature. He was therapeutically anticoagulated with heparin (target aPTT 70–90 seconds).

Over the subsequent 7 days after embolectomy, the patient developed progressive extremity necrosis and sepsis despite improving pulmonary function, prompting above-elbow amputation. The closure appeared clean with viable tissue for 2 weeks, and clinically, the patient recovered well enough to be extubated.

Thirteen days after amputation, new, progressive ischemia was noted at the incision line and anterior skin flap (Fig. 1). The ischemia spread posteriorly on postoperative day 14, with further epidermal sloughing and dermal necrosis. Stump debridement and coverage were planned; however, on postoperative day 18, the patient experienced neurologic deterioration with intraparenchymal hemorrhage. The patient's family decided to pursue comfort measures, and the patient died on postoperative day 21.

CAC is an emerging hallmark of the COVID-19 pandemic, contributing to macro- and microvascular complications. Mechanisms underlying CAC-induced tissue necrosis are not well understood and may be related to hypercoagulability, pathologic viral effects, or immune system hyperactivity.<sup>3,4</sup> Studies investigating the cutaneous manifestations of COVID-19-induced tissue ischemia have described thrombotic microangiopathy secondary to cold-sensitive antibody/immunoglobulin activation after viral infection,<sup>3</sup> or complement deposition in dermal capillaries and endothelial damage at the dermo-hypodermal junction.<sup>4</sup> Compromised blood flow secondary to hypercoagulability may be another mechanism. In the case presented, the characteristic uprending fibrinogen was most closely associated with observed progressive tissue necrosis (Fig. 2).

Surgeons may consider early hematologic consultation, a practice that has demonstrated improved outcomes in other patients at a high risk of perioperative thrombosis.<sup>5</sup>



**Fig. 1.** Anterior skin flap necrosis developed 2 weeks after transhumeral amputation.

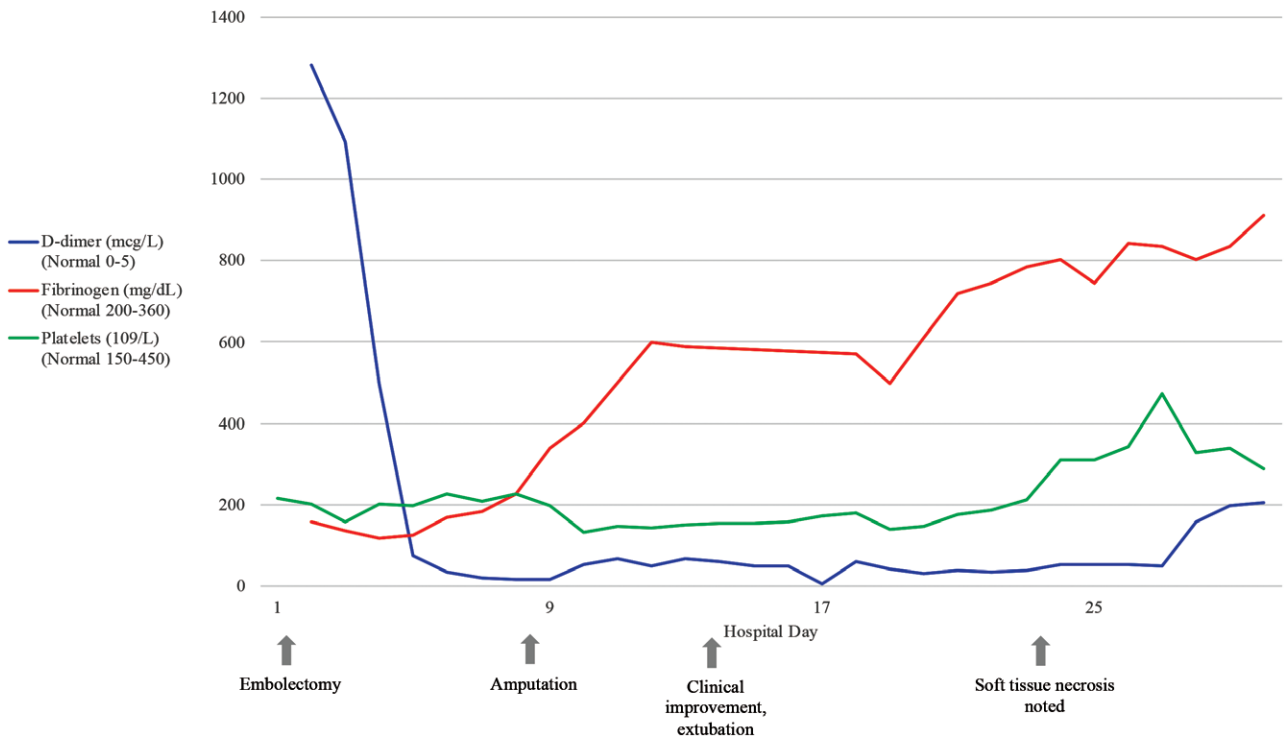
From the Division of Plastic and Reconstructive Surgery, Lewis Katz School of Medicine, Temple University, Philadelphia, Pa.

Received for publication October 27, 2020; accepted November 23, 2020.

Copyright © 2020 The Authors. Published by Wolters Kluwer Health, Inc. on behalf of The American Society of Plastic Surgeons. This is an open-access article distributed under the terms of the Creative Commons Attribution-Non Commercial-No Derivatives License 4.0 (CCBY-NC-ND), where it is permissible to download and share the work provided it is properly cited. The work cannot be changed in any way or used commercially without permission from the journal.

*Plast Reconstr Surg Glob Open* 2020;8:e3366; doi: 10.1097/GOX.0000000000003366; Published online 16 December 2020.

### Coagulation Profile



**Fig. 2.** Fibrinogen, D-dimer, and platelet changes over time. Rising fibrinogen levels were most closely associated with the development of progressive tissue necrosis.

As the clinical course of COVID-19 is clarified, further emphasis should be placed on studying lasting coagulation profile changes that affect the reconstructive outcome of both emergent and elective procedures.

**Christine M. Jones, MD**

Division of Plastic and Reconstructive Surgery  
 Temple University Hospital  
 3401 North Broad Street, 4<sup>th</sup> Floor  
 Parkinson Pavilion  
 Philadelphia, PA 19140  
 E-mail: [Christine.Jones@tuhs.temple.edu](mailto:Christine.Jones@tuhs.temple.edu)

#### DISCLOSURE

None of the authors has a financial interest in any of the products, devices, or drugs mentioned in this article.

#### REFERENCES

1. World Health Organization. WHO Coronavirus Disease (COVID-19) Dashboard. Updated November 17, 2020. Accessed November 17, 2020. <https://covid19.who.int>.
2. Becker RC. COVID-19 update: Covid-19-associated coagulopathy. *J Thromb Thrombolysis*. 2020;50:54–67.
3. Wang JS, Pasioka HB, Petronic-Rosic V, et al. Digital gangrene as a sign of catastrophic coronavirus disease 2019-related microangiopathy. *Plast Reconstr Surg Glob Open*. 2020;8:e3025.
4. Criado PR, Abdalla BMZ, de Assis IC, et al. Are the cutaneous manifestations during or due to SARS-CoV-2 infection/COVID-19 frequent or not? Revision of possible pathophysiologic mechanisms. *Inflamm Res*. 2020;69:745–756.
5. Pannucci CJ, Kovach SJ, Cuker A. Microsurgery and the hypercoagulable state: a hematologist’s perspective. *Plast Reconstr Surg*. 2015;136:545e–552e.