

Subtype transition from pemphigus vulgaris to pemphigus foliaceus



Ty Gilkey, BS,^a Alexander Hammond, BS,^b Pooja Gurnani, MD,^c Mahtab Forouzandeh, MD,^c Sylvia Hsu, MD,^d and Kiran Motaparthy, MD^c

Key words: bullous disease; immunobullous; pemphigus foliaceus; pemphigus subtype transition; pemphigus vulgaris.

INTRODUCTION

Pemphigus vulgaris (PV) and pemphigus foliaceus (PF) are autoimmune bullous disorders of the pemphigus family, characterized by autoantibodies against epidermal desmosome components desmoglein (Dsg) 1 and Dsg3.¹ PV is associated with painful intraepithelial blister development and is characterized by circulating and tissue-bound anti-Dsg3 immunoglobulin G (IgG) autoantibodies with or without anti-Dsg1 autoantibodies.² In contrast, PF is characterized by solely anti-Dsg1 autoantibodies, resulting in skin-limited disease. PF is characterized by subcorneal (intraepithelial) acantholysis in contrast to the suprabasilar acantholysis seen in PV.¹ To our knowledge, transition between PV and PF has rarely been reported in the literature and represents a unique immunological phenomenon. Here we report 4 cases of the pemphigus subtype transition from PV to PF.

CASE SERIES

Case 1

A 62-year-old man presented with eroded and crusted alopecic plaques on the scalp and hemorrhagic crusting of the lower vermilion lip and oral mucosa associated with extreme pain (Fig 1). A diagnosis of PV was confirmed with histopathologic findings demonstrating suprabasilar acantholysis, direct immunofluorescence (DIF) results revealing immunoreactivity for IgG and complement C3 (C3)

Abbreviations used:

| | |
|--------|-----------------------------------|
| C3: | complement C3 |
| DIF: | direct immunofluorescence |
| Dsg: | desmoglein |
| ELISA: | enzyme-linked immunosorbent assay |
| IgG: | immunoglobulin G |
| PF: | pemphigus foliaceus |
| PV: | pemphigus vulgaris |

in a netlike pattern within the epidermis, and enzyme-linked immunosorbent assay (ELISA) results demonstrating undetectable levels of autoantibodies directed against Dsg1 (<14 units/mL) and elevated levels of anti-Dsg3 antibodies (26 units/mL). Remission off therapy was achieved following a 4-month taper of prednisone (1 mg/kg/d), mycophenolate mofetil (1500 mg/d), and 1 cycle of rituximab (375 mg/m² weekly for 4 weeks). One year following remission, the patient presented with thin scaly plaques and superficial erosions limited to the scalp; at this time, there was no mucosal involvement (Fig 2). Repeat biopsy results were diagnostic for PF, revealing acantholysis within the granular layer of the epidermis and follicles. DIF results revealed immunoreactivity for IgG and C3 in a netlike pattern within the epidermis. ELISA revealed elevated levels of IgG autoantibodies against Dsg1 (29 units/mL) but with undetectable levels of anti-Dsg3 autoantibodies (<9 units/mL). Remission off therapy was achieved following treatment with azathioprine (150 mg/d)

From the College of Medicine, Ohio State University, Columbus, Ohio^a; University of Florida College of Medicine, Gainesville, Florida^b; Department of Dermatology, University of Florida, Gainesville, Florida^c; and Department of Dermatology, Lewis Katz School of Medicine, Temple University, Philadelphia, Pennsylvania.^d

Funding sources: None.

IRB approval status: Not applicable.

Patient Consent: Consent for the publication of all patient photographs and medical information was provided by the authors at the time of article submission to the journal stating that all patients gave consent for their photographs and medical information to be published in print and online and

with the understanding that this information may be publicly available.

Correspondence to: Kiran Motaparthy, MD, Department of Dermatology, University of Florida College of Medicine, 4037 NW 86 Terrace, 4th Floor Room 4123, Springhill, Gainesville, FL 32606. E-mail: kmotaparthy@dermatology.med.ufl.edu.

JAAD Case Reports 2023;31:31-4.

2352-5126

© 2022 by the American Academy of Dermatology, Inc. Published by Elsevier, Inc. This is an open access article under the CC BY-NC-ND license (<http://creativecommons.org/licenses/by-nc-nd/4.0/>).

<https://doi.org/10.1016/j.jidcr.2022.10.036>

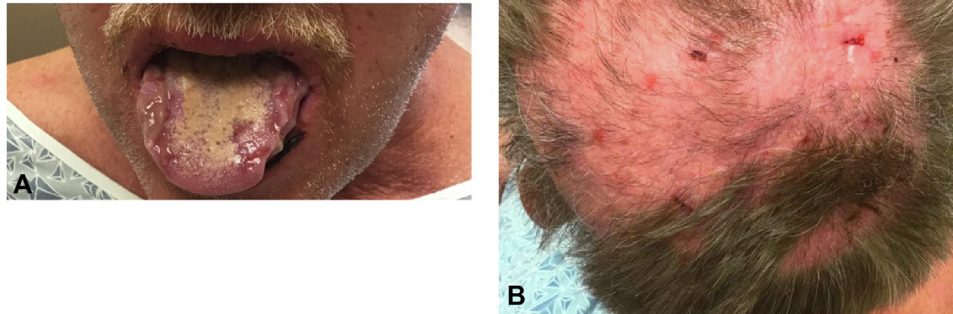


Fig 1. Pemphigus vulgaris. **A**, Oral mucosal erosions involving a large portion of the tongue. **B**, Large, pink alopecic plaque with scattered tufts of hair, crusts, and erosions on the scalp.

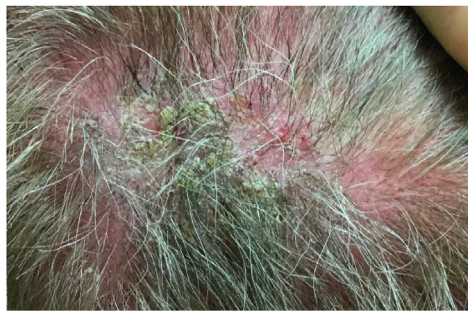

Fig 2. Pemphigus foliaceus. Thin plaques with cornflake scales and superficial erosions on the scalp.

and an additional cycle of rituximab (375 mg/m² weekly for 4 weeks).

Case 2

A 49-year-old woman presented initially with extensive erosions and flaccid bullae involving the oral mucosa, trunk, and scalp (Fig 3, A). A diagnosis of PV was confirmed by DIF, which demonstrated intercellular IgG and C3 depositions that were more prominent in the lower two-thirds of the epithelium. Her disease was poorly controlled on a regimen of mycophenolate mofetil, dapsone, and topical triamcinolone. Five years later, the patient presented with persistent, refractory hyperkeratotic plaques with areas of superficial erosion on the scalp, back, and legs but without mucosal involvement (Fig 3, B). ELISA demonstrated elevated levels of autoantibodies directed against Dsg1 (121 units/mL) but undetectable levels of anti-Dsg3 antibodies (<9 units/mL). These results, along with a seborrheic distribution and lack of mucosal involvement, were consistent with PF. The patient experienced remission off therapy following 1 cycle of rituximab (1 g intravenous on days 1 and 15), a 1-month prednisone taper (1 mg/kg/d), and azathioprine (100 mg daily).

Case 3

A 38-year-old man was diagnosed with mucocutaneous PV confirmed by histopathology and DIF. Remission off therapy was achieved following a prednisone taper combined with methotrexate. Sixteen years later, the patient presented with thin scaly plaques on the scalp, ears, forehead, and cheeks; however, there was no mucosal involvement. Punch biopsy demonstrated acantholysis within the granular layer and subcorneal pustules. DIF demonstrated cell surface IgG deposition in the upper two-thirds of the epidermis and follicular epithelium. ELISA revealed elevated levels of autoantibodies against Dsg1 (63 units/mL) but with undetectable levels of anti-Dsg3 antibodies (2 units/mL). The immunopathologic findings along with the seborrheic distribution of the lesions were consistent with PF. Remission was achieved 4 months after treatment with rituximab (375 mg/m² weekly for 4 weeks), clobetasol, and intralesional triamcinolone.

Case 4

A 28-year-old woman presented with flaccid and ruptured bullae on the face and back. Although histopathologic findings demonstrated subcorneal acantholysis, ELISA demonstrated levels of autoantibodies directed against both Dsg1 (209.7 units/mL) and Dsg3 (42.9 units/mL). One year later, the patient presented with a new single flaccid bulla on the back without mucosal involvement. ELISA demonstrated levels of autoantibodies against Dsg1 (34.9 units/mL), but anti-Dsg3 antibody levels were undetectable (<9 units/mL). At this time, the serologic findings were consistent with PF. The eruption resolved in several months following treatment with prednisone (1 mg/kg) and clobetasol.

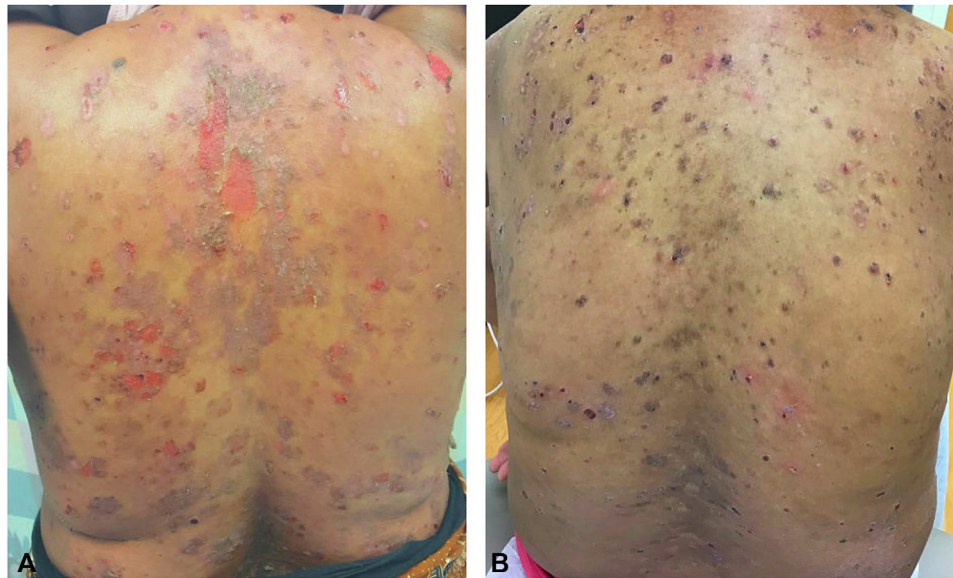

Fig 3. **A**, Pemphigus vulgaris. Deep erosions and crust involving the back. **B**, Pemphigus foliaceus. Superficial erosions with crust involving the back.

Table I. Published examples of subtype transition from pemphigus vulgaris to pemphigus foliaceus

| Authors and year | Age (y)/Sex | Method of diagnosis | Transition period (y) |
|---------------------------------------|--------------|-----------------------------|-----------------------|
| Iwatsuki et al, 1991 ⁸ | 36/F | Immunoblot | 3 |
| Iwatsuki et al, 1991 ⁸ | 58/F | Indirect immunofluorescence | 1.5 |
| Hashimoto et al, 1991 ⁴ | Not recorded | Immunoblot | 20 |
| Hashimoto et al, 1991 ⁴ | Not recorded | Immunoblot | 4 |
| Hashimoto et al, 1991 ⁴ | Not recorded | Immunoblot | 3 |
| Chang et al, 1997 ⁹ | 47/M | Immunoblot | 3 |
| Kimoto et al, 2001 ⁵ | 77/F | ELISA | 5 |
| Komai et al, 2002 ¹⁰ | 65 | ELISA | 1 |
| Komai et al, 2002 ¹⁰ | 46 | ELISA and immunoblot | 3 |
| Komai et al, 2002 ¹⁰ | 40 | ELISA and immunoblot | 1 |
| Komai et al, 2002 ¹⁰ | 50 | ELISA and immunoblot | 0.5 |
| Tsuji et al, 2002 ¹¹ | 55/M | ELISA | 3 |
| Harman et al, 2002 ⁷ | 44/F | ELISA | 5 |
| Tóth et al, 2002 ¹² | 28/M | ELISA | 2 |
| Ng and Thng, 2005 ¹³ | 29/M | ELISA | 4 |
| Ng and Thng, 2005 ¹³ | 56/M | ELISA | 2 |
| Ng and Thng, 2005 ¹³ | 45/F | ELISA | 2 |
| Lévy-Sitbon et al, 2013 ¹⁴ | 47/M | ELISA | 3 |
| Gilkey et al, 2022 | 62/M | ELISA | 0.5 |
| Gilkey et al, 2022 | 49/F | ELISA | 5 |
| Gilkey et al, 2022 | 54/M | ELISA | 16 |
| Gilkey et al, 2022 | 29/F | ELISA | 1 |

ELISA, Enzyme-linked immunosorbent assay; F, female; M, male.

DISCUSSION

This case series presents 4 cases of PV confirmed by DIF or ELISAs. Each patient initially achieved remission after treatment with varying combinations of immunosuppressants, including prednisone, mycophenolate mofetil, rituximab, methotrexate,

dapsone, or topical steroids. Each patient relapsed between 1 to 16 years after remission with a PF phenotype as confirmed by ELISAs. After the subtype transition to PF, each patient achieved remission following additional immunosuppression, with a heavy reliance on rituximab.

PV and PF are caused by autoantibodies against cadherin proteins known as desmogleins. Autoantibodies against only Dsg1 produce superficial acantholysis in PF. Autoantibodies directed against Dsg3 produce mucosal erosions in PV, although autoantibodies against Dsg3 and Dsg1 result in mucocutaneous PV.¹

One possible immunologic mechanism underlying the transition between PV and PF entails an epitope-spreading phenomenon. Epitope spreading results from a primary autoimmune or inflammatory process that causes tissue damage by exposing immunologically hidden proteins to the immune system, thereby evoking a secondary autoimmune response.³ The transition from PF to PV is thought to be due to epitope spreading, suggesting that autoantibodies develop against Dsg3 following severe keratinocyte damage and exposure of Dsg3, leading to a change in the clinical phenotype.^{4,5}

The mechanism underlying the transition from PV to PF, observed in this series, is less clear. Ding et al⁶ demonstrated that anti-Dsg1 autoantibodies in PV sera are pathogenic and that they induce typical PF lesions in neonatal mice. The transition from PV to PF may be mediated by the preferential suppression of anti-Dsg3 autoantibodies following immunosuppressive therapy, although ongoing production of anti-Dsg1 autoantibodies results in residual clinical findings of PF. Harman et al⁷ demonstrated that changes in antibody levels reflect phenotypic disease, but the permanence of this transition is unknown.

Previous reports reflecting the transition from PV to PF based on histopathology, immunoblot, and ELISAs are summarized in Table I.^{4,5,7-14} The transition from PV to PF is more common than from PF to PV.¹² Transition periods have varied from 6 months to 20 years, with a median length of 3 years. The median age of patients undergoing subtype transition was 47 years. Sexes are equally represented. The evolution of the preferred diagnostic modality from immunoblot assays to ELISA is highlighted in Table I. Quantitative detection of anti-Dsg1 and anti-Dsg3 autoantibodies by ELISA is the most accurate diagnostic test for PV and PF. Histopathologic classification is imprecise in up to 40% of cases of pemphigus (as observed in case 4), and false negative results may be observed with immunoblots.¹⁰

The main limitation of this case series is the inconsistency of diagnostic techniques; ideally, each patient would have routine histopathology, DIF, and ELISA performed at both the initial presentation and at the time of clinical subtype transition. Differentiation between PV and PF is important for

medical management and disease prognosis.¹⁵ Although rare, the transition from PV to PF represented in this case series highlights the importance of adequate follow-up for patients with PV. Larger studies of subtype transition may identify individual risk factors and confirm the pathogenesis of this unique phenomenon.

Conflicts of interest

None disclosed.

REFERENCES

1. Malik AM, Tupchong S, Huang S, Are A, Hsu S, Motaparthy K. An updated review of pemphigus diseases. *Medicina (Kaunas)*. 2021;57(10):1080.
2. Scully C, Challacombe SJ. Pemphigus vulgaris: update on etiopathogenesis, oral manifestations, and management. *Crit Rev Oral Biol Med*. 2002;13(5):397-408.
3. Didona D, Di Zenzo G. Humoral epitope spreading in autoimmune bullous diseases. *Front Immunol*. 2018;9:779.
4. Hashimoto T, Konohana A, Nishikawa T. Immunoblot assay as an aid to the diagnoses of unclassified cases of pemphigus. *Arch Dermatol*. 1991;127(6):843-847.
5. Kimoto M, Ohyama M, Hata Y, Amagai M, Nishikawa T. A case of pemphigus foliaceus which occurred after five years of remission from pemphigus vulgaris. *Dermatology*. 2001;203(2):174-176.
6. Ding X, Diaz LA, Fairley JA, Giudice GJ, Liu Z. The anti-desmoglein 1 autoantibodies in pemphigus vulgaris sera are pathogenic. *J Invest Dermatol*. 1999;112(5):739-743.
7. Harman KE, Gratian MJ, Shirlaw PJ, Bhogal BS, Challacombe SJ, Black MM. The transition of pemphigus vulgaris into pemphigus foliaceus: a reflection of changing desmoglein 1 and 3 autoantibody levels in pemphigus vulgaris. *Br J Dermatol*. 2002;146(4):684-687.
8. Iwatsuki K, Takigawa M, Hashimoto T, Nishikawa T, Yamada M. Can pemphigus vulgaris become pemphigus foliaceus? *J Am Acad Dermatol*. 1991;25(5 Pt 1):797-800.
9. Chang SN, Kim SC, Lee IJ, Seo SJ, Hong CK, Park WH. Transition from pemphigus vulgaris to pemphigus foliaceus. *Br J Dermatol*. 1997;137(2):303-305.
10. Komai A, Amagai M, Ishii K, et al. The clinical transition between pemphigus foliaceus and pemphigus vulgaris correlates well with the changes in autoantibody profile assessed by an enzyme-linked immunosorbent assay. *Br J Dermatol*. 2001;144(6):1177-1182.
11. Tsuji Y, Kawashima T, Yokota K, et al. Clinical and serological transition from pemphigus vulgaris to pemphigus foliaceus demonstrated by desmoglein ELISA system. *Arch Dermatol*. 2002;138(1):95-96.
12. Tóth GG, Pas HH, Jonkman MF. Transition of pemphigus vulgaris into pemphigus foliaceus confirmed by antidesmoglein ELISA profile. *Int J Dermatol*. 2002;41(8):525-527.
13. Ng PPL, Thng STG. Three cases of transition from pemphigus vulgaris to pemphigus foliaceus confirmed by desmoglein ELISA. *Dermatology*. 2005;210(4):319-321.
14. Lévy-Sitbon C, Reguiai Z, Durlach A, Goedel AL, Grange F, Bernard P. Transition from pemphigus vulgaris to pemphigus foliaceus: a case report. Article in French. *Ann Dermatol Venereol*. 2013;140(12):788-792.
15. Pan M, Liu X, Zheng J. The pathogenic role of autoantibodies in pemphigus vulgaris. *Clin Exp Dermatol*. 2011;36(7):703-707.