

Disconnected Pancreatic Duct Syndrome: Pancreatitis of the Disconnected Pancreas and Its Role in the Development of Diabetes Mellitus

Nikhil R. Thiruvengadam, MD^{1,2,3,4}, Kimberly A. Forde, MD, PhD⁵, Janille Miranda, BS⁴, Christopher Kim, MD⁶, Spencer Behr, MD⁶, Umesh Masharani, MBBS⁷ and Mustafa A. Arain, MD^{4,8}

INTRODUCTION: Disconnected pancreatic duct syndrome (DPDS) is a recognized complication of necrotizing pancreatitis (NP). Manifestations include recurrent peripancreatic fluid collections (R-PFC) and pancreaticocutaneous fistulae (PC-Fistulae). Pancreatitis of the disconnected pancreatic segment (DPDS-P) and its relationship to new-onset diabetes after pancreatitis (NODAP) are not well characterized.

METHODS: We performed a retrospective cohort study of consecutive patients with NP admitted to University of California, San Francisco from January 2011 to June 2019. A diagnosis of a disconnected pancreatic duct (PD) was confirmed using computed tomography and magnetic resonance cholangiopancreatography/endoscopic retrograde cholangiopancreatography. DPDS was defined as a disconnected PD presenting with R-PFC, PC-Fistulae, or DPDS-P. The primary outcome was NODAP, defined as diabetes mellitus (DM) occurring >3 months after NP. Cox proportional hazards regression was used to evaluate the relationship between DPDS and NODAP.

RESULTS: Of 171 patients with NP in this study, the mean clinical follow-up was 46 ± 18 months and the imaging follow-up was 38 ± 20 months. Twenty-seven patients (16%) developed DPDS-P at a median of 28 months. New-onset DM occurred in 54 of the 148 patients (36%), with 22% developing DM within 3 months of NP and 14% developing NODAP at a median of 31 months after AP. DPDS-P was associated with NODAP when compared with non-DPDS patients (adjusted hazard ratio 5.63 95% confidence interval: 1.69–18.74, $P = 0.005$) while R-PFCs and PC-Fistulae were not.

DISCUSSION: DPDS and NODAP occurred in 28% and 14% of the patients, respectively. Pancreatitis of the disconnected pancreas occurred in 16% of the patients and was associated with higher rates of NODAP when compared with patients with other manifestations of DPDS and patients without DPDS.

SUPPLEMENTARY MATERIAL accompanies this paper at <http://links.lww.com/CTG/A755>, <http://links.lww.com/CTG/A756>, <http://links.lww.com/CTG/A757>, <http://links.lww.com/CTG/A758>, <http://links.lww.com/CTG/A759>, <http://links.lww.com/CTG/A760>, <http://links.lww.com/CTG/A761>

Clinical and Translational Gastroenterology 2022;13:e00457. <https://doi.org/10.14309/ctg.000000000000457>

INTRODUCTION

Disconnected pancreatic duct syndrome (DPDS) is a clinical syndrome that most commonly occurs in necrotizing pancreatitis (NP) where necrosis in a segment of the pancreas leads to a lack of continuity between the upstream viable pancreas (and associated pancreatic duct [PD]) and the duodenum (1–3). By contrast, patients

with a PD leak or disruption have an intact PD with a leak from the main PD or a side branch (2). Studies have found that up to 74% of the patients with NP may have a disconnected PD/segment (4–8). Clinical manifestations associated with DPDS include the development of recurrent peripancreatic fluid collections (R-PFC) and persistent pancreaticocutaneous fistulae (PC-Fistulae) after resolution

¹Division of Gastroenterology and Hepatology, Loma Linda University School of Medicine, Loma Linda, California, USA; ²Division of Gastroenterology and Hepatology, University of Pennsylvania, Philadelphia, Pennsylvania, USA; ³Center for Endoscopic Innovation, Research and Training, Perelman School of Medicine at the University of Pennsylvania, Philadelphia, Pennsylvania, USA; ⁴Division of Gastroenterology and Hepatology, University of California San Francisco, San Francisco, California, USA; ⁵Division of Gastroenterology and Hepatology, Temple University, Philadelphia, Pennsylvania ⁶Abdominal Imaging Section, Department of Radiology, University of California San Francisco, San Francisco, California, USA; ⁷Division of Endocrinology and Metabolism, Department of Medicine, The University of California, San Francisco, California, USA.; ⁸Center for Interventional Endoscopy, AdventHealth, Orlando, Florida, USA. **Correspondence:** Mustafa Arain, MD. E-mail: mustafa.arain.md@adventhealth.com.

Received March 2, 2021; accepted December 28, 2021; published online February 19, 2022

© 2022 The Author(s). Published by Wolters Kluwer Health, Inc. on behalf of The American College of Gastroenterology

of NP (1,9–14). Acute and chronic pancreatitis (AP and CP) of the disconnected pancreas are not well-recognized complications of DPDS (15). In the recent long-term follow-up of the PANcreatitis Necrosectomy versus sTEp up appRoach trial (PANTER) trial, the incidence of DPDS and pancreatitis of the disconnected pancreas (DPDS-P) was reported to be 11% and 5.4%, respectively (16).

New-onset diabetes mellitus after pancreatitis (NODAP) is a known complication of pancreatitis. It is commonly associated with chronic pancreatitis; however, recent studies have shown that it can be associated with acute pancreatitis as well, with up to 15% of the patients with AP developing NODAP (17–19). Beyond the loss of islet cells, potential mechanisms of NODAP include chronic inflammation, peripheral insulin resistance, and alteration in pancreatic hormonal signaling (20–26). In the long-term follow-up of the PANTER trial, the incidence of NODAP was 36% at a mean follow-up of 86 months. Another study of patients with NP treated nonsurgically found that 15% developed NODAP at a median of 36 months (27). The relationship between DPDS and new-onset diabetes mellitus (DM) has recently been described; however, it is not known whether this association is because of pancreatitis of the disconnected pancreas or other manifestations of DPDS (8,28).

In this retrospective cohort study, we evaluate the relationship between DPDS-associated manifestations and NODAP in a consecutive series of patients with NP. We hypothesized that pancreatitis of the disconnected pancreas is associated with an increased risk of NODAP.

METHODS

We conducted a retrospective cohort study at the University of California, San Francisco Medical Center. We identified all patients admitted with AP from January 1, 2011, to July 1, 2019, using the *International Classification of Disease (ICD)-9* codes 577.0/577.8 and *ICD-10* codes 85.0–3 and 85.8. A total of 2942 patients were identified. Their charts were reviewed manually (by N.T. and J.M.) to identify patients with NP.

As part of our clinical approach, a multidisciplinary team (gastroenterology/surgery/radiology) evaluated patients and a consensus was reached on diagnosis, need for intervention, and intervention strategy. A step-up percutaneous approach was used from 2011 to 2016. After 2016, a step-up endoscopic approach (and/or percutaneous drainage) was introduced as the primary approach. Primary open necrosectomy was reserved for patients when minimally invasive approaches were not possible (see Supplementary Index 1, Supplementary Digital Content 1, <http://links.lww.com/CTG/A757>). For patients treated endoscopically, Lumen Apposing Metal Stent (LAMS) with coaxial double-pigtail stents through the lumen of the LAMS were used and these double-pigtail stents were left in place after LAMS removal.

Follow-up

All patients had the clinical follow-up with a repeat contrast-enhanced computed tomography (CECT) scan 3–6 months after their last intervention, and for residual collections, a CECT/magnetic resonance imaging (MRI) was repeated 3–6 months later. Subsequently, imaging was repeated as clinically indicated, and asymptomatic patients did not have repeat imaging.

Disconnected Pancreatic Duct Syndrome

DPDS was defined as the following:

Magnetic resonance cholangiopancreatography (MRCP)/endoscopic retrograde cholangiopancreatography (ERCP)

demonstrating a disconnected PD with a CECT or MRI demonstrating a viable distal segment of the pancreas and one of the following (29):

1. R-PFC: discrete fluid collection after resolution of the initial NP collection adjacent to the disconnected pancreas with associated symptoms (abdominal pain, nausea, or vomiting). Patients with NP who were treated using a conservative approach had to have radiographic resolution of their initial necrotic collection and the development of a new collection to be considered as having an R-PFC.
2. PC-Fistula: a persistent output of amylase-rich fluid from a percutaneous drain or previous drainage tract after complete resolution of the initial necrotic collection. Enterocutaneous fistulae were not included in the definition of DPDS.
3. DPDS-AP: acute pancreatitis (30) with CECT showing radiologic findings of AP limited to the disconnected pancreas. This includes peripancreatic inflammatory changes characterized by peripancreatic tissues demonstrating haziness with fat stranding, peripancreatic edema, lack of normal enhancement of the pancreatic parenchyma, and pancreatic and peripancreatic fluid collections/necrotic collections (31).
4. DPDS-CP: symptoms of chronic pancreatitis with radiologic signs of chronic pancreatitis in the disconnected pancreas per the M-ANNHEIM diagnostic criteria (marked, moderate or mild duct lesions of the DPD, and calcifications) that have been used in the PANTER trial to assess the disconnected pancreas (16,32). Imaging modalities used to diagnose DPDS-CP included CT, MRI, and/or endoscopic ultrasound.

Asymptomatic patients with a confirmed disconnected PD/segment were defined as having a disconnected PD/segment and not DPDS. A disrupted PD was defined as filling of the PD on ERCP to the tail of the pancreas with extravasation of contrast from a focal area of duct injury (33). Patients with disrupted PDs were not considered to have DPDS.

Abdominal radiologists (C.K. and S.B.) reviewed all imaging at admission, before intervention, and after intervention. MRCP and ERCPs were reviewed to identify a duct disconnection, and contrast-enhanced MRI and/or CT were reviewed to evaluate for the presence of disconnected pancreatic parenchyma and changes in the disconnected pancreas over time.

New-onset diabetes after pancreatitis

DM was defined as new-onset elevation in fasting glucose ≥ 126 mg/dL, 2-hour glucose ≥ 200 mg/dL after an oral glucose tolerance test, or hemoglobin A1c $> 6.5\%$ (34). To facilitate standardization, an American Diabetic Association definition of NODAP has been proposed defining it as new-onset diabetes that occurs more than 3 months after the onset of acute pancreatitis (35). This definition distinguishes NODAP from pre-existing undiagnosed DM (because a hemoglobin A1c represents glucose values for the previous 2–3 months), stress hyperglycemia, and DM due to pancreatic parenchymal and islet cell loss due to pancreatic necrosis that can occur early in the course of acute NP. In our study, we define NODAP as a primary outcome. An assessment of DM was performed during post-pancreatitis follow-up visits in the first year and then as clinically indicated. Patients were censored at the time of the last evaluation for diabetes mellitus.

Outcomes

The primary outcome for our study was the development of NODAP as defined above.

Table 1. Baseline characteristics of the overall cohort

Factor, n (%) or median (IQR)	Overall (N = 171)
Clinical characteristics	
Age	52 (36, 62)
Sex	
Female	68 (39.8%)
Male	103 (60.2%)
Body mass index	27 (21–34)
Race	
White	88 (51.4%)
Black	19 (11.1%)
Hispanic	43 (25.1%)
Asian	19 (11.0%)
Other	2 (1.2%)
Etiology	
Alcohol	48 (28.1%)
Biliary	62 (36.3%)
Idiopathic	33 (19.3%)
Post-ERCP	12 (7.0%)
Other	16 (9.4%)
ASA class at admission	
1	4 (2.3%)
2	88 (51.5%)
3	79 (46.2%)
Charlson Comorbidity Index	3 (1, 4)
Characteristics of necrosis	
Location of necrosis	
Head	8 (4.7%)
Head/body	55 (32.2%)
Body	27 (15.8%)
Body/tail	65 (38.0%)
Tail	16 (9.4%)
Necrotic collection size anterior-posterior (cm)	10 (6.8, 14.8)
Necrotic collection size transverse (cm)	8 (5.5, 11)
Necrotic collection extends into the pelvis	102 (60.0%)
Presentation	
Uninfected necrosis	47 (27.5%)
Confirmed infected necrosis	124 (72.5%)
Admission severity scores	
Simplified acute physiology score II	24 (16, 33)
APACHE II score	9 (5, 14)
Modified organ dysfunction score	1 (0, 2)
mCTSI	8 (6, 10)
Organ failure on admission	
SOF on admission	64 (37.4%)
MOF on admission	30 (17.5%)
Types of organ failures on admission	

Table 1. (continued)

Factor, n (%) or median (IQR)	Overall (N = 171)
Respiratory	64 (37.2%)
Cardiovascular	57 (33.3%)
Renal	109 (63.4%)
Required ICU during hospital stay	127 (74.2%)
Intervention characteristics	
Treatment strategy	
Conservative management	29 (17.0%)
Percutaneous drainage only	27 (15.8%)
Endoscopic transluminal drainage/necrosectomy	28 (16.4%)
Endoscopic transluminal drainage/necrosectomy + percutaneous drainage	20 (11.7%)
Percutaneous drainage + surgical debridement	40 (23.4%)
Minimally invasive surgery alone	7 (4.1%)
Open surgery	20 (11.7%)
DPDS characteristics	
Developed DPDS	48 (28%)
Imaging to evaluate DPDS	
CT/MRCP	13 (27%)
CT/ERCP	35 (73%)
Location of disconnection	
Head/neck	18 (38%)
Body	26 (54%)
Tail	4 (8%)
Diabetes characteristics	
Early-onset/stress hyperglycemia/previously undiagnosed	33 (19%)
New-onset diabetes after pancreatitis (NODAP, >3 mo onset)	21 (12.2%)
Tests used to diagnose NODAP	
Fasting glucose >126 mg/dL	2 (10%)
Hemoglobin A1c > 6.5%	19 (90%)
Median hemoglobin A1c at the time of NODAP diagnosis	8.7%
Insulin dependence in NODAP pts	11 (52%)

APACHE, Acute Physiology and Chronic Health Evaluation; ASA, American Society of Anesthesiologists; CT, computed tomography; DPDS, disconnected pancreatic duct syndrome; ERCP, endoscopic retrograde cholangiopancreatography; ICU, intensive care unit; LOS, length of stay; mCTSI, modified computed tomography severity index; MOF, multiple organ failure; MRCP, magnetic retrograde cholangiopancreatography; NODAP, new-onset diabetes after pancreatitis; SOF, single-organ failure.

Statistical analysis

Patient data collected included demographics, hospitalization data, timing, and types of interventions, and imaging studies performed. Differences in demographic and/or clinicopathological variables between the cohorts were analyzed using the χ^2 and

Downloaded from http://journals.lww.com/cg by BMDM5ePHKav1ZEoum1IQIN4a+kJLHEZgpsiH04XMI0hCwCCT1AWN YqplIQHHD3i3D00DRy7T/SF14C3V/C1y0abggQZXdgGj2MwZLel= on 11/03/2023

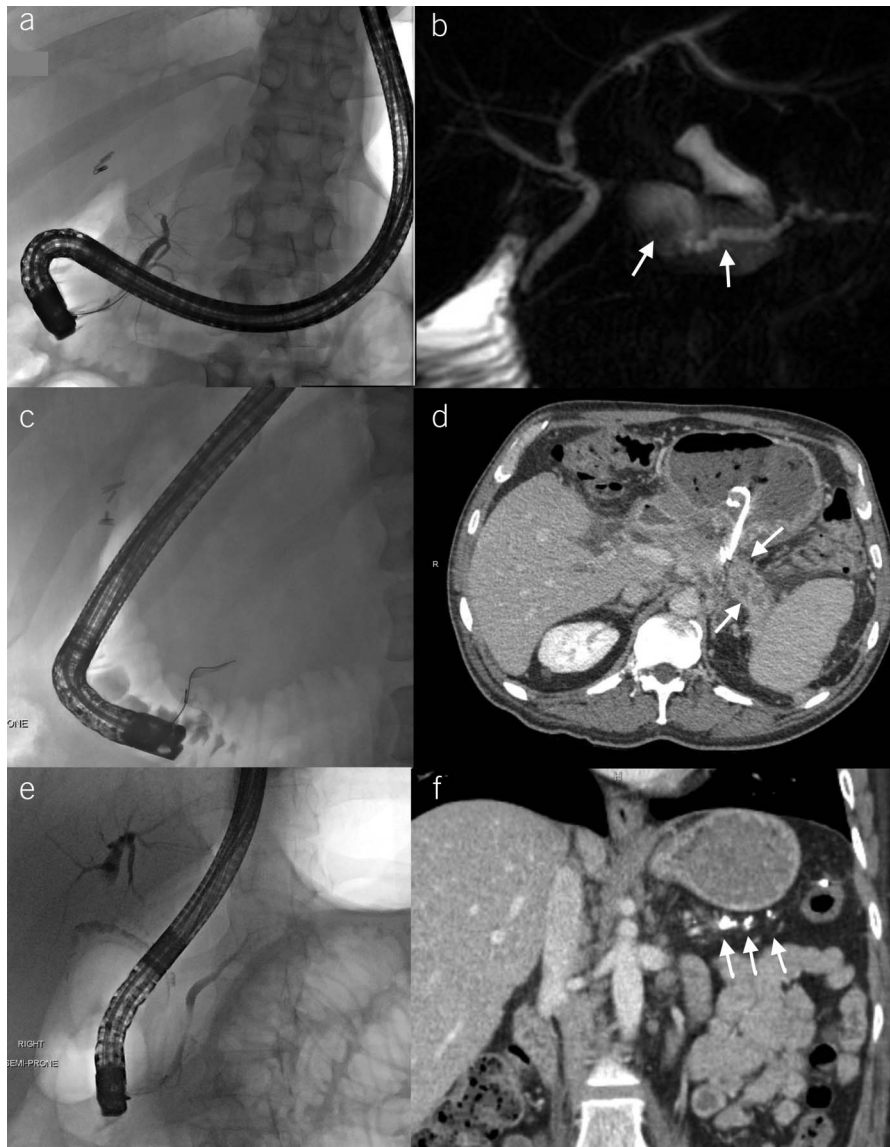


Figure 1. (a and b) ERCP and MRCP demonstrating a recurrent peripancreatic fluid collection and a dilated, disconnected pancreatic duct. (c and d): ERCP and CT demonstrating a disconnected pancreatic segment with surrounding peripancreatic fat stranding and inflammatory changes consistent with acute pancreatitis. Cystogastrostomy plastic stents are seen adjacent to the disconnected pancreas. (e and f) ERCP and CT demonstrating calculi in the main duct and side branches consistent with chronic calcific pancreatitis of the disconnected pancreatic segment with sparing of the pancreatic duct in the head and neck. CT, computed tomography; ERCP, endoscopic retrograde cholangiopancreatography; MRCP, magnetic resonance cholangiopancreatography.

Fisher exact tests for categorical variables and the Student *t* test and Wilcoxon rank sum tests for continuous variables, as appropriate.

For each patient, we determined whether they developed DPDS (R-PFC, PC-Fistulae, DPDS-AP, and/or DPDS-CP). Next, we determined whether patients developed NODAP.

Cumulative incidence curves were plotted with mortality as a competing risk (36). The association between NODAP and DPDS was estimated using a multivariable Cox proportional hazards model. The effect of mortality as a competing event was also modeled by calculating subhazard ratios (SHRs), with the use of the method of Fine and Gray (36). Forward stepwise regression was used, and the development of DPDS was treated as a time-varying covariate (see Supplementary Index 2, Supplementary

Digital Content 2, <http://links.lww.com/CTG/A758>). Secondary propensity-matched models were created to account for potential unmeasured confounders and inherent differences between the cohorts.

All statistical analyses were performed with STATA 15 statistical package (StataCorp LP, College Station, TX). A *P* value of < 0.05 was considered statistically significant.

RESULTS

We identified 171 patients with NP. The mean clinical follow-up was 46 ± 18 months, and the mean radiographic follow-up (with CT or MRI) was 38 ± 20 months. Thirty-one patients (18.1%) were managed using a conservative approach, consisting of enteral nutritional support and antibiotics as needed, whereas 140

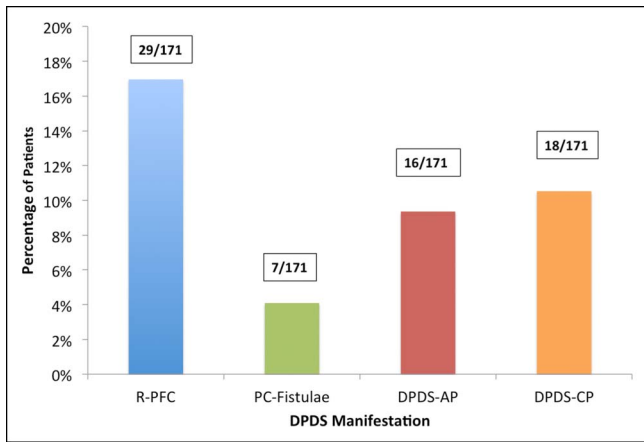


Figure 2. Incidence of disconnected pancreatic duct syndrome manifestations.

patients (81.9%) underwent intervention. Eighteen patients (10.5%) died during the study period. Baseline characteristics are summarized in Table 1.

Forty-eight patients (28.1%) developed DPDS (median 13.5 [interquartile range [IQR] 6–38] months, Figure 1), of whom 19 patients (11.1%) developed more than 1 DPDS manifestation (see Supplementary Index 3, Supplementary Digital Content 3, <http://links.lww.com/CTG/A759>). The rate of DPDS was 40% (42 patients) in 104 patients who had at least 36 months of the radiographic follow-up. Thirty-four patients (71%) required hospitalization for DPDS (median length of stay 11 [IQR 5–15] days). Fifty-five patients (33%) underwent ERCP to assess for a DPD compared with 116 patients who underwent CECT/MRCP alone (67%). Thirty-five of the 55 patients (64%) who underwent ERCP were diagnosed with DPDS. Thirteen of the 116 patients (11%) who had MRCP alone were diagnosed with DPDS. Twelve patients (7%) had a PD disruption and were treated with a transpapillary pancreatic stent placement.

DPDS manifestations

Twenty-nine patients (16.9%) developed an R-PFC and 7 (4%) developed a PC-Fistula. (Figure 2, see Supplementary Figure 1, Supplementary Digital Content 4, <http://links.lww.com/CTG/A755>). Details of DPDS manifestations based on initial intervention for NP are presented in Supplementary Figure 2, Supplementary Digital

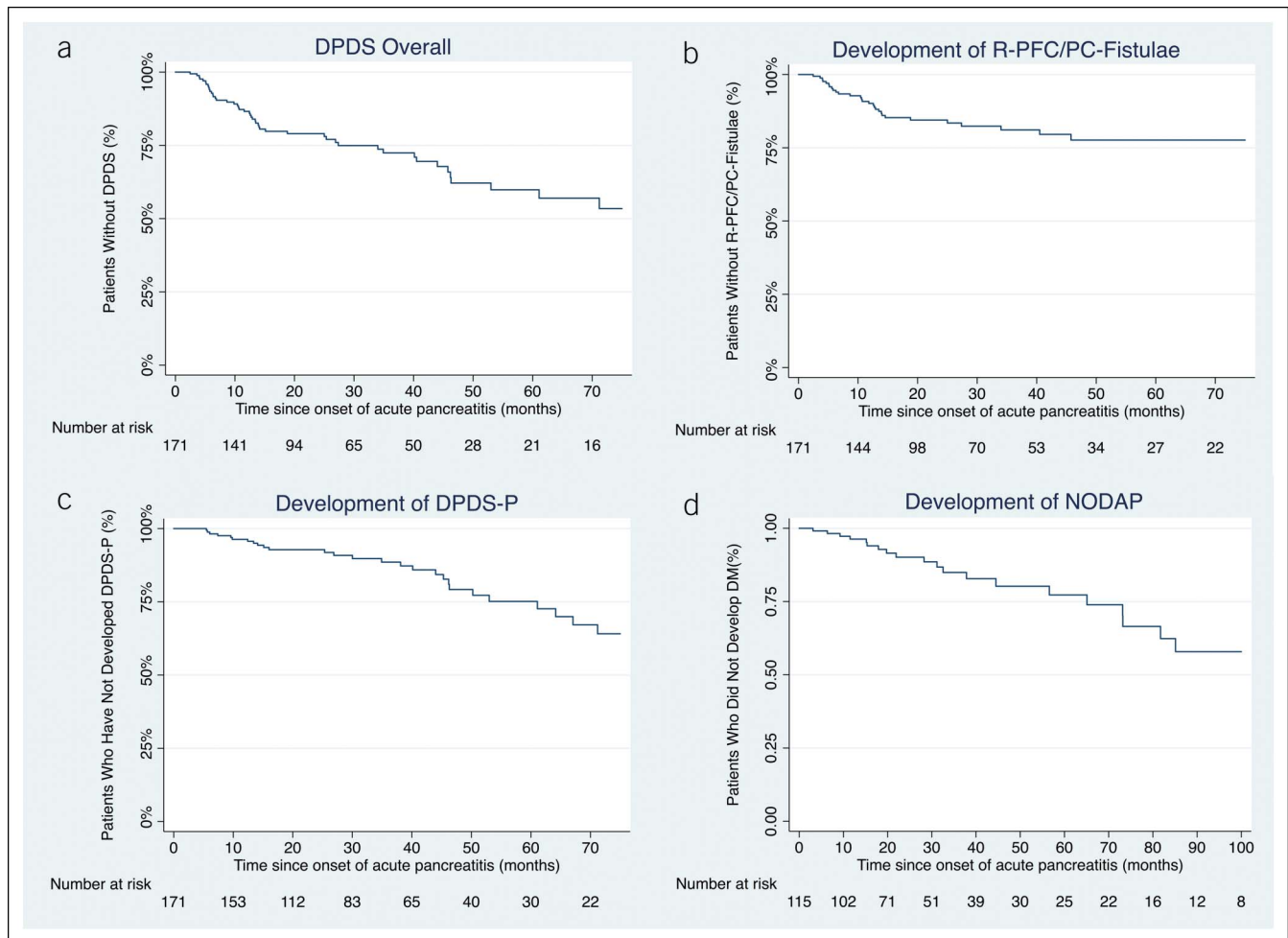


Figure 3. (a) A cumulative incidence curve for DPDS. (b) A cumulative incidence curve for R-PFCs/PC-fistulae. (c) A cumulative incidence curve for DPDS-P. (d) A cumulative incidence curve for NODAP. DPDS, disconnected pancreatic duct syndrome; DPDS-P, disconnected pancreatic segment; NODAP, new-onset diabetes after pancreatitis; PC-Fistulae, pancreaticocutaneous fistulae; R-PFC, recurrent peripancreatic fluid collection.

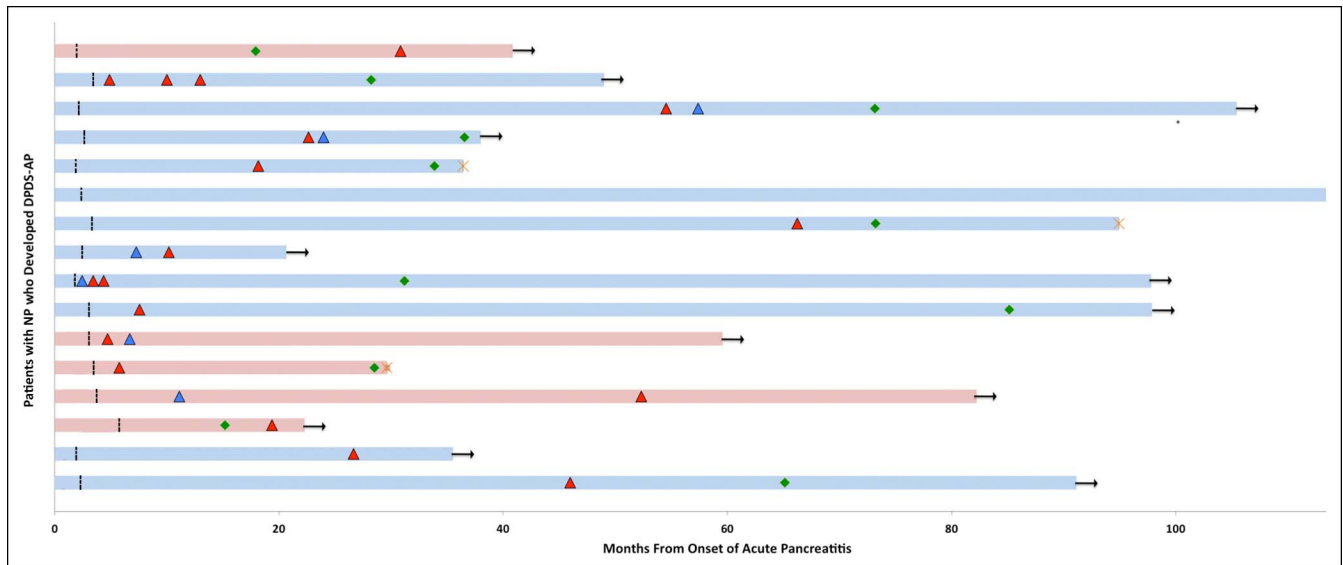


Figure 4. Swimmer plot demonstrating the clinical course of DPDS-AP. Each lane represents the clinical course of a single patient. Patients in red received long-term indwelling transmural stents while the patients in blue did not. The blue triangles represent development of a R-PFC, while the red triangle represents the development of DPDS-AP. The Green diamond represents development of NODAP. Finally, the arrow at the end of the lane indicates ongoing follow-up while the red X at the end of the lane indicates a patient lost to follow-up. DPDS-AP, disconnected pancreatic duct syndrome-acute pancreatitis.

Content 5, <http://links.lww.com/CTG/A756>. Twenty-seven patients (15.7%) developed DPDS-P (9 acute, 11 chronic, and 7 acute and chronic pancreatitis, Figure 3). The median time to development of DPDS-P was 28 months (IQR 13–46, $P = 0.002$) and was significantly longer than the time to development of R-PFC/PC-Fistulae (7 months [IQR 5–14], $P = 0.002$). Patients with DPDS-AP had a median of 2 (2–3) hospitalizations (median length of stay of 14 (13–27) days; Figure 5). Details for interventions for DPDS are given in Supplementary Index 4, Supplementary Digital Content 6, links.lww.com/CTG/A760.

Development of NODAP

Of the 171 patients with NP, 23 (7 with DPDS) had pre-existing DM. Thirty ERCP patients (6 with DPDS) were diagnosed as having diabetes within 3 months of presentation with NP due to stress hyperglycemia, true early-onset DM, or undiagnosed DM before the onset of NP and were excluded from the analysis of NODAP, leaving 115 patients at risk for developing NODAP (Figure 4). NODAP developed in 21 of the 115 patients (18.2%) at a median of 31 (IQR 15–56) months.

DPDS and NODAP. Among 115 patients at risk, 15 of the 35 patients (43%) with DPDS developed NODAP compared with 6 of the 80 patients (7.5%) without DPDS. DPDS was associated with a higher risk of NODAP when compared with patients without DPDS (sHR 3.2, 95% CI 1.3–12.03, $P = 0.01$).

DPDS-P and NODAP. Patients who developed DPDS-P had a much higher rate of NODAP compared with patients with DPDS who did not have pancreatitis of the disconnected pancreas and patients without DPDS (13/23 [56%] vs 2/12 [16.7%] vs 6/80 [7.5%], respectively, $P = 0.007$). Patients with DPDS-P had a significantly higher rate of development of NODAP when compared with patients without DPDS (sHR 5.63, 95% confidence interval [CI]: 1.69–18.74, $P = 0.005$ after adjustment for age and

type of management of NP). The propensity-matched analysis confirmed these results (sHR 4.07, 95% CI: 0.97–17.11, $P = 0.05$). When compared with patients with DPDS who did not have pancreatitis of the disconnected pancreas, patients with DPDS-P had a higher risk of NODAP (sHR 4.2, 95% CI [0.82–7.74], $P = 0.11$). Surgical resection of the DPD in patients with DPDS-P was not the primary driving factor for developing NODAP (2 patients with DPDS-P underwent distal pancreatectomy/splenectomy and 1 developed NODAP).

DPDS without pancreatitis of the disconnected pancreas and NODAP

Patients with DPDS without pancreatitis of the disconnected pancreas did not have a higher rate of NODAP when compared with patients without DPDS (sHR 0.58, 95% CI: 0.18–1.90, $P = 0.38$).

Site of duct disconnection and NODAP

The site of PD disconnection was not associated with a risk of NODAP on a univariable analysis, and it was not an effect modifier or confounder for the relationship between DPDS-P and NODAP.

DISCUSSION

In this cohort of consecutive patients with NP, we found that the incidence of DPDS was 28% (48/171 patients). An R-PFC or PC-Fistula occurred in 17% of the patients, and DPDS-P, an under-reported manifestation, occurred in 16% of the patients and had a more delayed presentation (28 vs 7 months, $P = 0.002$). New-onset DM occurred in 36% of the patients with NP, with 22% developing DM within 3 months of NP potentially reflecting previously unrecognized diabetes, stress hyperglycemia, or pancreatic necrosis resulting in islet cell destruction. Fourteen percent of the patients developed NODAP at a median of 31 months after AP. Patients with DPDS-P were more likely to develop

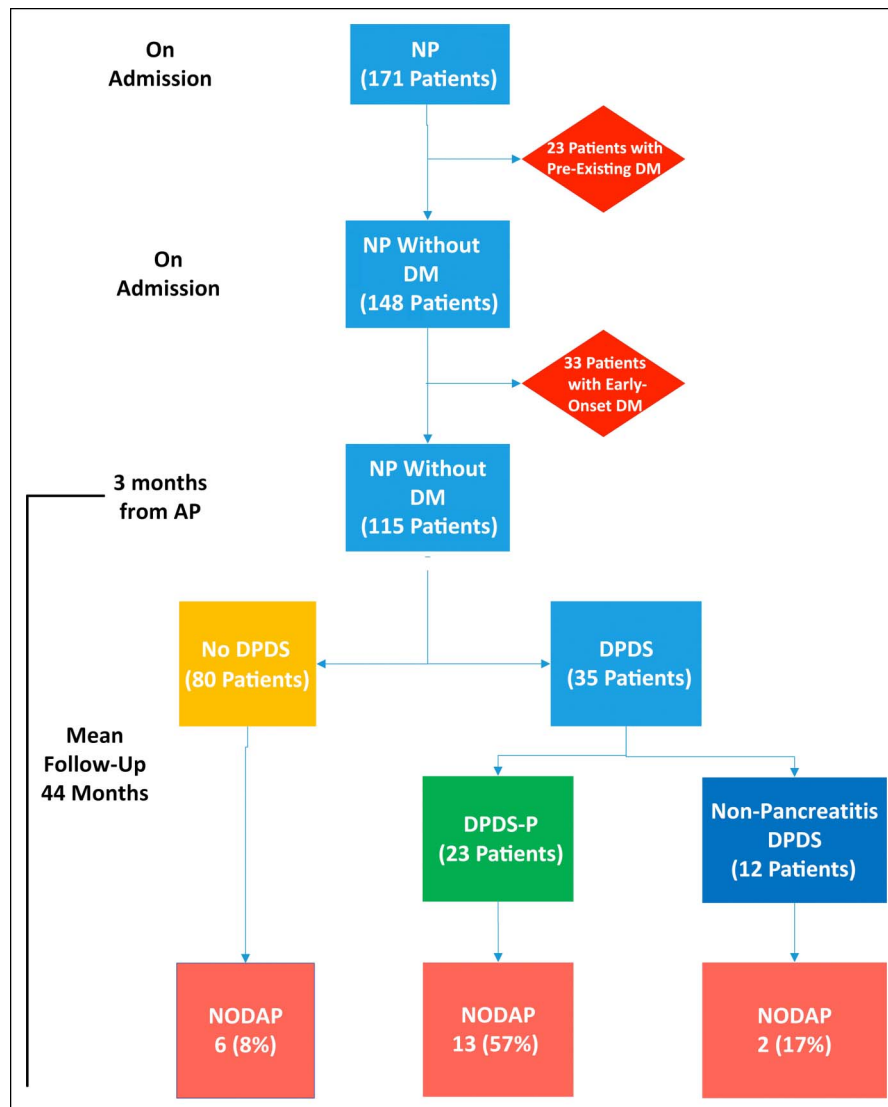


Figure 5. Flow-chart for diabetes mellitus in our cohort.

NODAP (57%) compared with those without DPDS (8%) and those with DPDS without pancreatitis of the disconnected pancreas (17%, $P = 0.007$).

There is increasing interest in the development of post-pancreatitis diabetes mellitus and the underlying mechanisms responsible for it. Historically, new-onset diabetes in the setting of NP was believed to be associated with the loss of pancreatic tissue because of the development of necrosis and/or its treatment, i.e., necrosectomy. In this regard, the PANTER trial demonstrated a lower incidence of early-onset DM in patients treated with a step-up percutaneous approach compared with open necrosectomy. However, at the long-term follow-up, there were no differences in NODAP between the 2 arms suggesting alternative mechanisms for the development of NODAP (16,37). More recent studies have shown that in the short term, NODAP rates were not significantly different based on the type of minimally invasive treatment strategy used in the management of NP (38,39).

Our study is the first to comprehensively characterize the relationship between DPDS manifestations and development of

NODAP. Previous studies have shown that there may be a relationship between DPDS and development of DM after NP (8,28). We found that patients who developed DPDS-P had a much higher rate of NODAP compared with patients with other DPDS manifestations and patients without DPDS (56% vs 17% vs 8%, respectively). This suggests that in the setting of DPDS, NODAP may occur because of the loss of islet function in the disconnected pancreas secondary to persistent inflammation and fibrosis of the disconnected pancreatic segment. This process is likely partly dependent on the size of the disconnected pancreas (and therefore, the amount of viable islet cells) at risk of exposure to inflammatory damage. Although the site of disconnection was not associated with NODAP in our study, this has to be differentiated from the amount of pancreas lost and conversely the amount of viable disconnected pancreas that is left intact as a consequence of NP. Our findings highlight the need for further exploration of the association of DPDS-P and NODAP. In addition, further studies are needed to examine the impact of different DPDS treatment strategies on the development of NODAP (13,40).

In our study of consecutive patients with NP, 16% developed DPDS-P (5.2% AP, 6.4% CP, and 4.1% AP/CP). Importantly, patients developed DPDS-P independent of an initial management strategy and significantly later than R-PFC/PC-Fistulae (28 vs 7 months, $P = 0.002$). In contrast to R-PFC/PC-Fistulae, a mechanism of DPDS-P may involve scarring that prevents enzyme secretion through the DPD, potentially resulting in ductal hypertension and injury of the disconnected viable pancreas, which may in some patients lead to atrophy. The prolonged time to diagnosis is compounded by a lack of awareness of DPDS-P and recognition of a disconnected pancreas on imaging studies (41). Indeed, in our study, 2 patients had multiple episodes of AP before DPDS was eventually diagnosed. The incidence of DPDS-P did not differ based on the initial treatment strategy for NP, including those treated using a conservative approach. Because there is no consensus definition for chronic pancreatitis of the DPD, we had to use imaging findings that are used in the M-ANNHEIM and Cambridge classifications to define DPDS-CP as had been performed in a previous study (16,32,42). This highlights the need to develop standardized diagnostic criteria for both AP and CP of the disconnected pancreas. Early recognition and intervention for DPDS-P may potentially ameliorate ongoing injury and attenuate the risk for NODAP.

There are several limitations to our study. First, although a multidisciplinary process was used in the management of NP, there was significant variation in the types of interventions in our patient population. This partly reflects the heterogeneous nature of NP that necessitates individualized treatment strategies and partly our evolution to a more minimally invasive approach over time. Second, we may be underestimating the true incidence of DPDS because of a lack of routine follow-up imaging, patients being lost to follow-up, and their symptoms not being recognized. The lack of routine ERCP in all patients also likely contributed to underestimating the prevalence of an asymptomatic DPD or asymptomatic DPDS (such as an R-PFC without associated symptoms). However, patients had a median imaging follow-up of 38 months. We observed a similar incidence of DPDS when we restricted the analysis to patients with at least 3 years of the radiographic and clinical follow-up. Third, given our study's retrospective design, there were several differences in the baseline characteristics between cohorts in our study, and although we adjusted for potential confounders, inherent differences could exist between different groups. Another limitation is that we used *ICD-9* and *ICD-10* codes to identify patients with AP, so there could have been a misclassification bias that resulted in some patients with AP not being identified. Because we manually reviewed all the identified patients and confirmed that they met the inclusion criteria, we feel the likelihood of misclassification of AP or NP is low. Finally, we did not measure and explore the relationship between the size of the disconnected pancreatic segment and manifestations of symptomatic DPDS. Our results need to be validated externally and may not be generalizable to all clinical settings in which NP is encountered.

In conclusion, in this large, consecutive series of patients with NP, symptomatic DPDS occurred in 28% of the patients overall and in 40% of the patients with the imaging follow-up at 3 years. The incidence of recurrent pancreatitis of the disconnected pancreas in our cohort was 16%. New-onset DM after NP occurred in 14% of the patients. Patients with DPDS-P had

substantially higher rates of NODAP than patients with other manifestations of DPDS and patients without DPDS, highlighting that pancreatitis of the disconnected pancreas may be one potential mechanism for NODAP. In our opinion, a consensus definition of DPDS is needed and it should include pancreatitis of the disconnected pancreatic segment, an important late and underrecognized complication. Further prospective studies are needed to better understand early detection, prevention, and treatment of pancreatitis of the disconnected viable pancreas and the development of diabetes after NP.

CONFLICTS OF INTEREST

Guarantor of the article: Mustafa Arain, MD.

Specific author contributions: N.R.T. and M.A. designed the study; N.R.T., J.M., C.K., S.B., and M.A. acquired the data; N.R.T. analyzed the data; and N.R.T., K.F., U.M., and M.A. interpreted the data and performed the statistical analyses. N.R.T. and M.A. wrote the manuscript. N.R.T., M.A., K.F., U.M., and J.M. helped revise the manuscript. All authors reviewed the data and analytic methods and contributed to the manuscript.

Financial support: None to report.

Potential competing interests: M.A. is a consultant for Boston Scientific, Olympus America, and Medtronic. The rest of the authors have no conflicts to disclose.

Study Highlights

WHAT IS KNOWN

- ✓ Disconnected pancreatic duct syndrome (DPDS) is a known complication of necrotizing pancreatitis.
- ✓ Patients with acute pancreatitis have an increased risk of new-onset diabetes mellitus after pancreatitis (NODAP).
- ✓ The relationship between DPDS, recurrent pancreatitis of the disconnected pancreas, and NODAP has not been well established.

WHAT IS NEW HERE

- ✓ Pancreatitis of the disconnected pancreas is an underrecognized complication of DPDS occurring in 16% of the patients.
- ✓ Patients with pancreatitis of the disconnected pancreas had a 5-fold higher risk of developing NODAP when compared with patients without DPDS.
- ✓ Further studies are needed to better elucidate the mechanisms behind this relationship.

REFERENCES

1. Tann M, Maglinte D, Howard TJ, et al. Disconnected pancreatic duct syndrome: Imaging findings and therapeutic implications in 26 surgically corrected patients. *J Comput Assist Tomogr* 2003;27:577–82.
2. Kozarek RA, Ball TJ, Patterson DJ, et al. Endoscopic transpapillary therapy for disrupted pancreatic duct and peripancreatic fluid collections. *Gastroenterology* 1991;100:1362–70.
3. Larsen M, Kozarek RA. Management of disconnected pancreatic duct syndrome. *Curr Treat Options Gastroenterol* 2016;14:348–59.
4. Neoptolemos JP, London NJ, Carr-Locke DL. Assessment of main pancreatic duct integrity by endoscopic retrograde pancreatography in patients with acute pancreatitis. *Br J Surg* 1993;80:94–9.
5. Bang JY, Wilcox CM, Navaneethan U, et al. Impact of disconnected pancreatic duct syndrome on the endoscopic management of pancreatic fluid collections. *Ann Surg* 2018;267:561–8.

6. Ross AS, Irani S, Gan SI, et al. Dual-modality drainage of infected and symptomatic walled-off pancreatic necrosis: Long-term clinical outcomes. *Gastrointest Endosc* 2014;79:929–35.
7. Maatman TK, Roch AM, Ceppa EP, et al. The continuum of complications in survivors of necrotizing pancreatitis. *Surgery* 2020;168:1032–40.
8. Basha J, Lakhtakia S, Nabi Z, et al. Impact of disconnected pancreatic duct on recurrence of fluid collections and new-onset diabetes: Do we finally have an answer? *Gut* 2021;70:447–9.
9. Lawrence C, Howell DA, Stefan AM, et al. Disconnected pancreatic tail syndrome: Potential for endoscopic therapy and results of long-term follow-up. *Gastrointest Endosc* 2008;67:673–9.
10. Fischer TD, Gutman DS, Hughes SJ, et al. Disconnected pancreatic duct syndrome: Disease classification and management strategies. *J Am Coll Surg* 2014;219:704–12.
11. Uomo G, Molino D, Visconti M, et al. The incidence of main pancreatic duct disruption in severe biliary pancreatitis. *Am J Surg* 1998;176:49–52.
12. Fotoohi M, D'Agostino HB, Wollman B, et al. Persistent pancreatocutaneous fistula after percutaneous drainage of pancreatic fluid collections: Role of cause and severity of pancreatitis. *Radiology* 1999;213:573–8.
13. Baron TH, DiMaio CJ, Wang AY, et al. American gastroenterological association clinical practice update: Management of pancreatic necrosis. *Gastroenterology* 2020;158:67–75 e1.
14. Rana SS, Sharma R, Kang M, et al. Natural course of low output external pancreatic fistula in patients with disconnected pancreatic duct syndrome following acute necrotizing pancreatitis. *Pancreatol* 2020;20:177–81.
15. Howard TJ, Moore SA, Saxena R, et al. Pancreatic duct strictures are a common cause of recurrent pancreatitis after successful management of pancreatic necrosis. *Surgery* 2004;136:909–16.
16. Hollemans RA, Bakker OJ, Boermeester MA, et al. Superiority of step-up approach vs open necrosectomy in long-term follow-up of patients with necrotizing pancreatitis. *Gastroenterology* 2019;156:1016–26.
17. Hart PA, Bellin MD, Andersen DK, et al. Type 3c (pancreatogenic) diabetes mellitus secondary to chronic pancreatitis and pancreatic cancer. *Lancet Gastroenterol Hepatol* 2016;1:226–37.
18. Malecka-Panas E, Gasirowska A, Kropiwnicka A, et al. Endocrine pancreatic function in patients after acute pancreatitis. *Hepatogastroenterology* 2002;49:1707–12.
19. Das SL, Singh PP, Phillips AR, et al. Newly diagnosed diabetes mellitus after acute pancreatitis: A systematic review and meta-analysis. *Gut* 2014;63:818–31.
20. Gillies N, Pendharkar SA, Asrani VM, et al. Interleukin-6 is associated with chronic hyperglycemia and insulin resistance in patients after acute pancreatitis. *Pancreatol* 2016;16:748–55.
21. Gillies NA, Pendharkar SA, Singh RG, et al. Fasting levels of insulin and amylin after acute pancreatitis are associated with pro-inflammatory cytokines. *Arch Physiol Biochem* 2017;123:238–48.
22. Pendharkar SA, Singh RG, Chand SK, et al. Pro-inflammatory cytokines after an episode of acute pancreatitis: Associations with fasting gut hormone profile. *Inflamm Res* 2018;67:339–50.
23. Gillies NA, Pendharkar SA, Singh RG, et al. Lipid metabolism in patients with chronic hyperglycemia after an episode of acute pancreatitis. *Diabetes Metab Syndr* 2017;11(suppl 1):S233–S241.
24. Pendharkar SA, Singh RG, Petrov MS. Pro-inflammatory cytokine-induced lipolysis after an episode of acute pancreatitis. *Arch Physiol Biochem* 2018;124:401–9.
25. Pendharkar SA, Asrani VM, Xiao AY, et al. Relationship between pancreatic hormones and glucose metabolism: A cross-sectional study in patients after acute pancreatitis. *Am J Physiol Gastrointest Liver Physiol* 2016;311:G50–8.
26. Pendharkar SA, Drury M, Walia M, et al. Gastrin-releasing peptide and glucose metabolism following pancreatitis. *Gastroenterol Res* 2017;10:224–34.
27. Uomo G, Gallucci F, Madrid E, et al. Pancreatic functional impairment following acute necrotizing pancreatitis: Long-term outcome of a non-surgically treated series. *Dig Liver Dis* 2010;42:149–52.
28. Nabi Z, Basha J, Lakhtakia S, et al. Disconnected pancreatic duct in children with walled OFF necrosis: Impact on outcomes of endoscopic drainage. *J Pediatr Gastroenterol Nutr* 2019;69:116–119.
29. Timmerhuis HC, van Dijk SM, Verdonk RC, et al. Various modalities accurate in diagnosing a disrupted or disconnected pancreatic duct in acute pancreatitis: A systematic review. *Dig Dis Sci* 2021;66:1415–24.
30. Banks PA, Bollen TL, Dervenis C, et al. Classification of acute pancreatitis—2012: Revision of the atlanta classification and definitions by international consensus. *Gut* 2013;62:102–11.
31. Foster BR, Jensen KK, Bakis G, et al. Revised atlanta classification for acute pancreatitis: A pictorial essay. *Radiographics* 2016;36:675–87.
32. Schneider A, Lohr JM, Singer MV. The M-ANNHEIM classification of chronic pancreatitis: Introduction of a unifying classification system based on a review of previous classifications of the disease. *J Gastroenterol* 2007;42:101–19.
33. Varadarajulu S, Noone TC, Tutuian R, et al. Predictors of outcome in pancreatic duct disruption managed by endoscopic transpapillary stent placement. *Gastrointest Endosc* 2005;61:568–75.
34. Rickels MR, Bellin M, Toledo FG, et al. Detection, evaluation and treatment of diabetes mellitus in chronic pancreatitis: Recommendations from PancreasFest 2012. *Pancreatol* 2013;13:336–42.
35. Petrov MS. Diabetes of the exocrine pancreas: American diabetes association-compliant lexicon. *Pancreatol* 2017;17:523–6.
36. Fine JP, Gray RJ. A proportional hazards model for the subdistribution of a competing risk. *J Am Stat Assoc* 1999;94:496–509.
37. van Santvoort HC, Besselink MG, Bakker OJ, et al. A step-up approach or open necrosectomy for necrotizing pancreatitis. *N Engl J Med* 2010;362:1491–502.
38. Bang JY, Arnoletti JP, Holt BA, et al. An endoscopic transluminal approach, compared with minimally invasive surgery, reduces complications and costs for patients with necrotizing pancreatitis. *Gastroenterology* 2019;156:1027–40 e3.
39. van Brunschot S, van Grinsven J, van Santvoort HC, et al. Endoscopic or surgical step-up approach for infected necrotizing pancreatitis: A multicentre randomised trial. *Lancet* 2018;391:51–8.
40. Trikudanathan G, Wolbrink DRJ, van Santvoort HC, et al. Current concepts in severe acute and necrotizing pancreatitis: An evidence-based approach. *Gastroenterology* 2019;156:1994–2007 e3.
41. Thiruvengadam NR, Miranda J, Kim C, et al. Burden of ionizing radiation in the diagnosis and management of necrotizing pancreatitis. *Clin Transl Gastroenterol* 2021;12:e00347.
42. Axon AT, Classen M, Cotton PB, et al. Pancreatography in chronic pancreatitis: International definitions. *Gut* 1984;25:1107.

Open Access This is an open access article distributed under the terms of the Creative Commons Attribution-Non Commercial-No Derivatives License 4.0 (CCBY-NC-ND), where it is permissible to download and share the work provided it is properly cited. The work cannot be changed in any way or used commercially without permission from the journal.